

GH1:

A case of lower jaw. 4 extracted teeth produced 4ml of autogenous dentin to be grafted into sockets and augmenting the buccal plate.

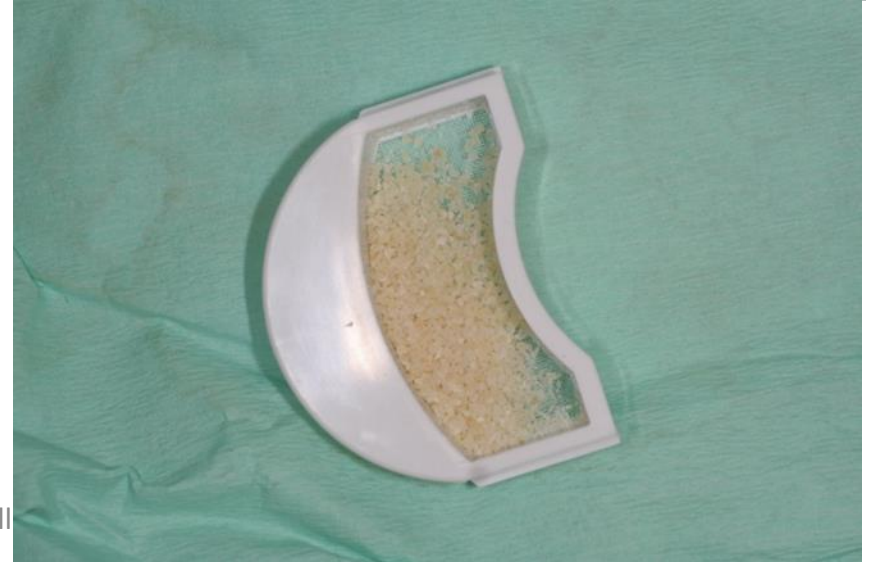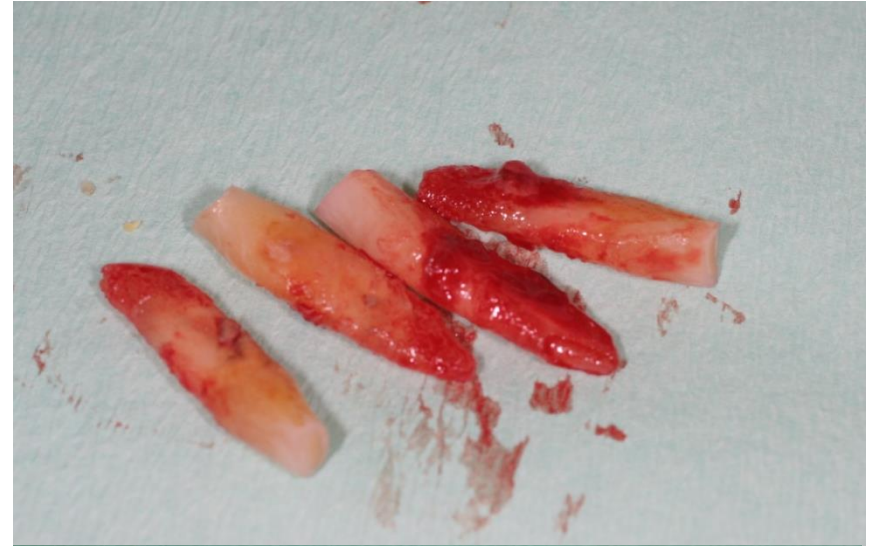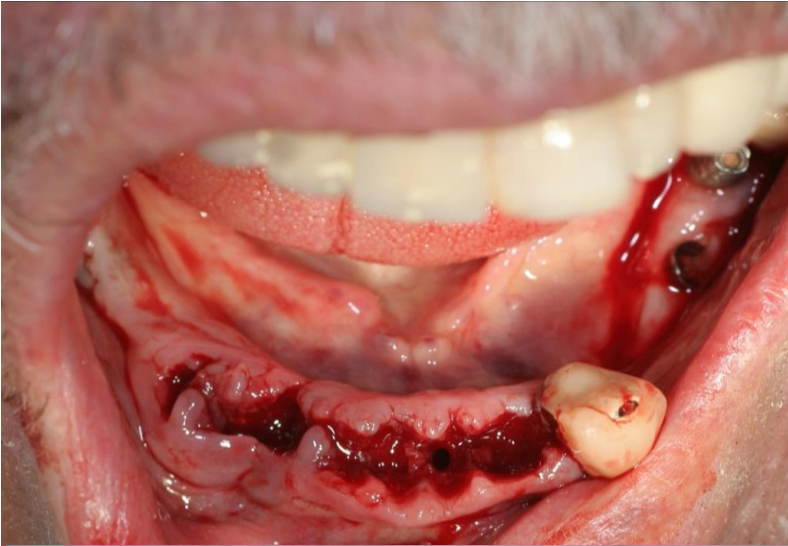
The implants were inserted in same session between the extracted sockets.

24 hours later an aesthetic temporary restoration was placed.

See: 5 month later the preserved bone level.

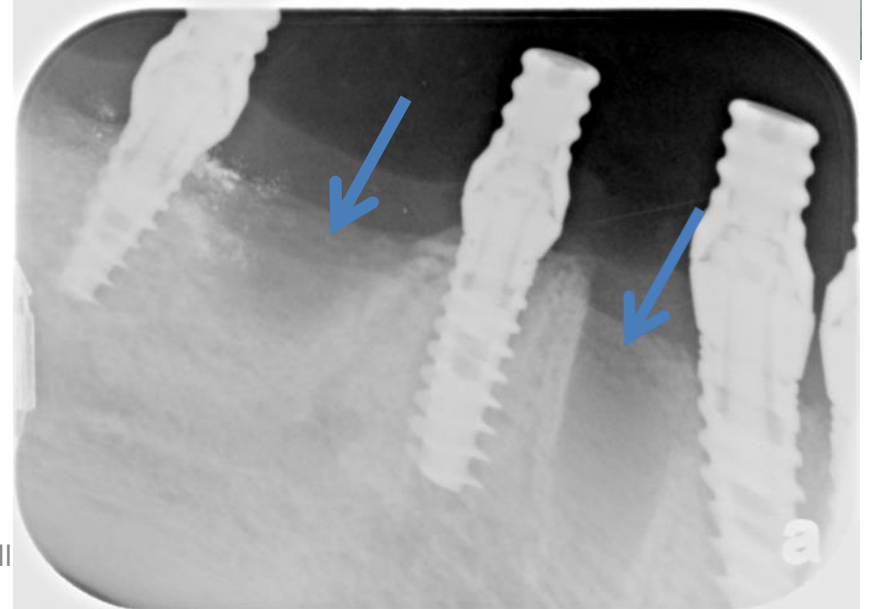
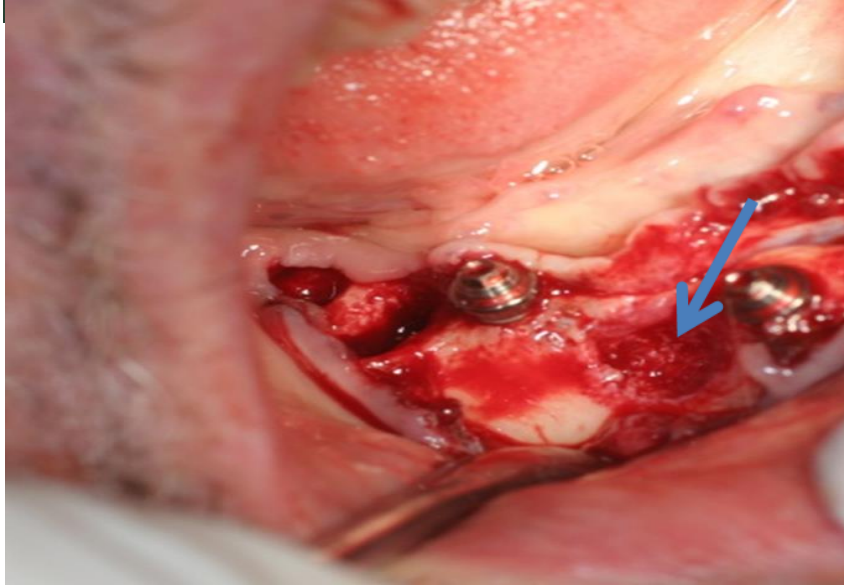
Case GH1

First step: extraction of teeth



CaseGH1

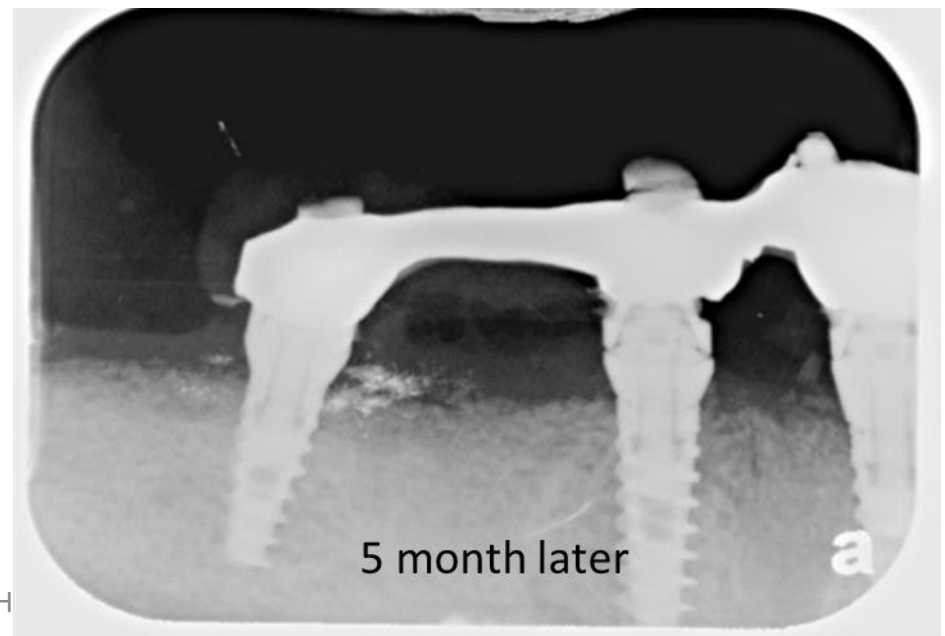
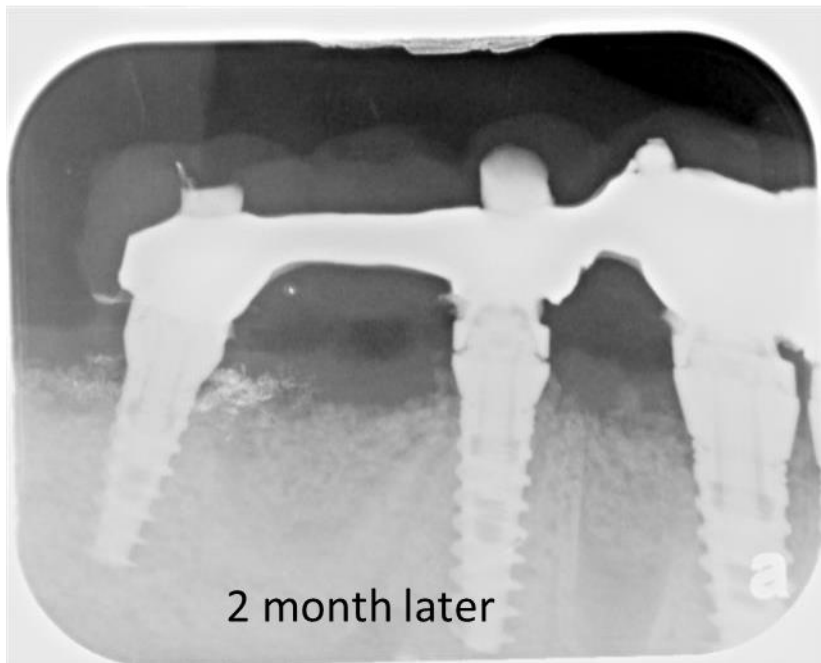
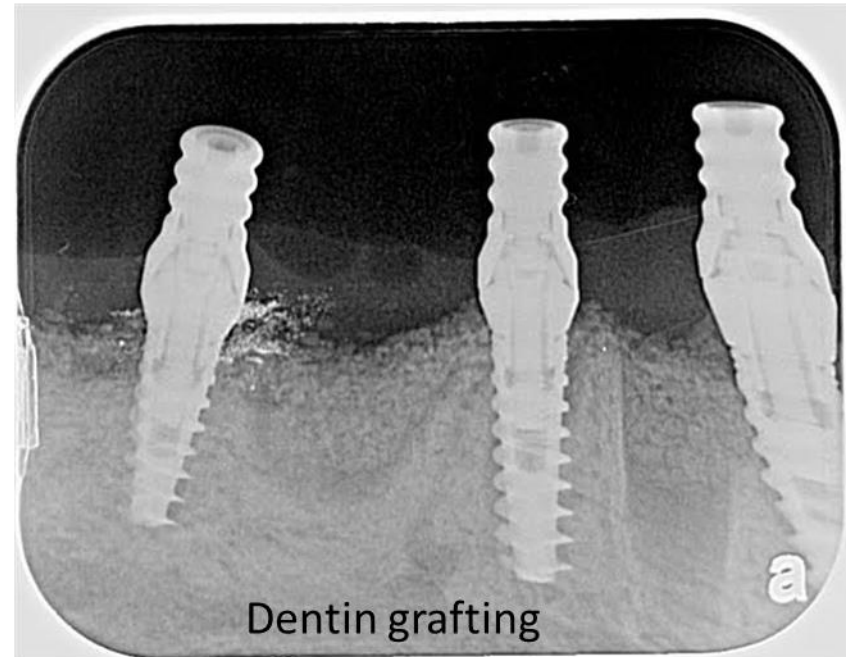
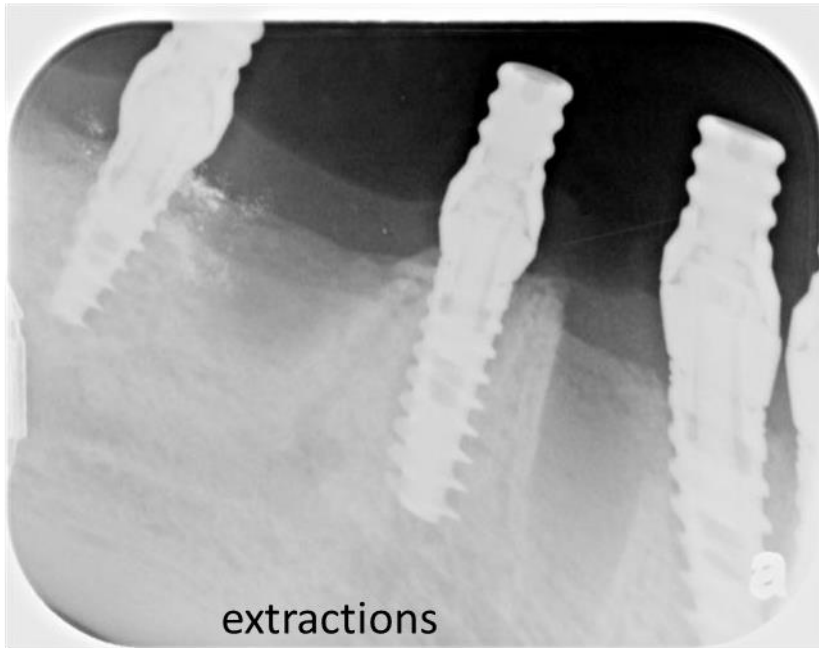
PRF membrane & Liquid



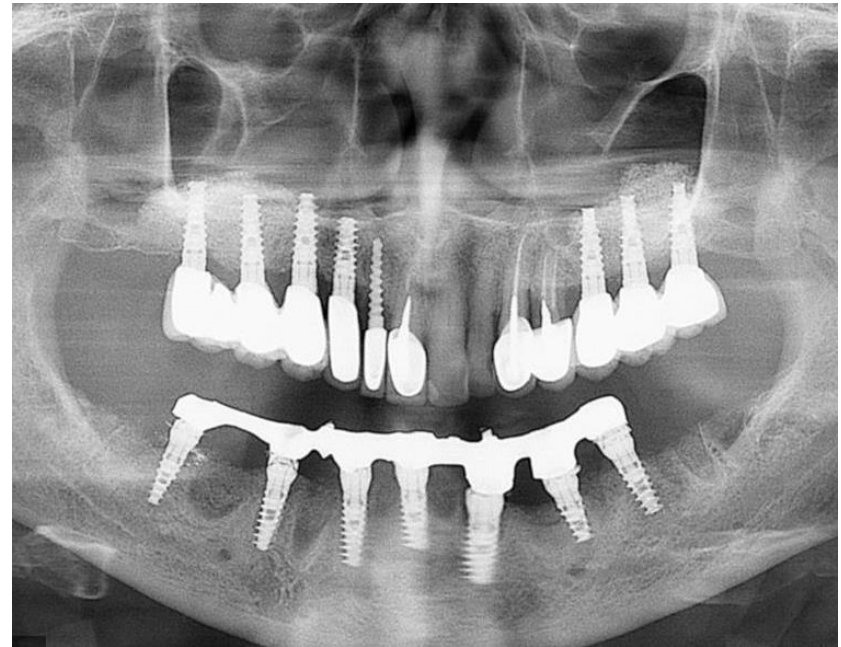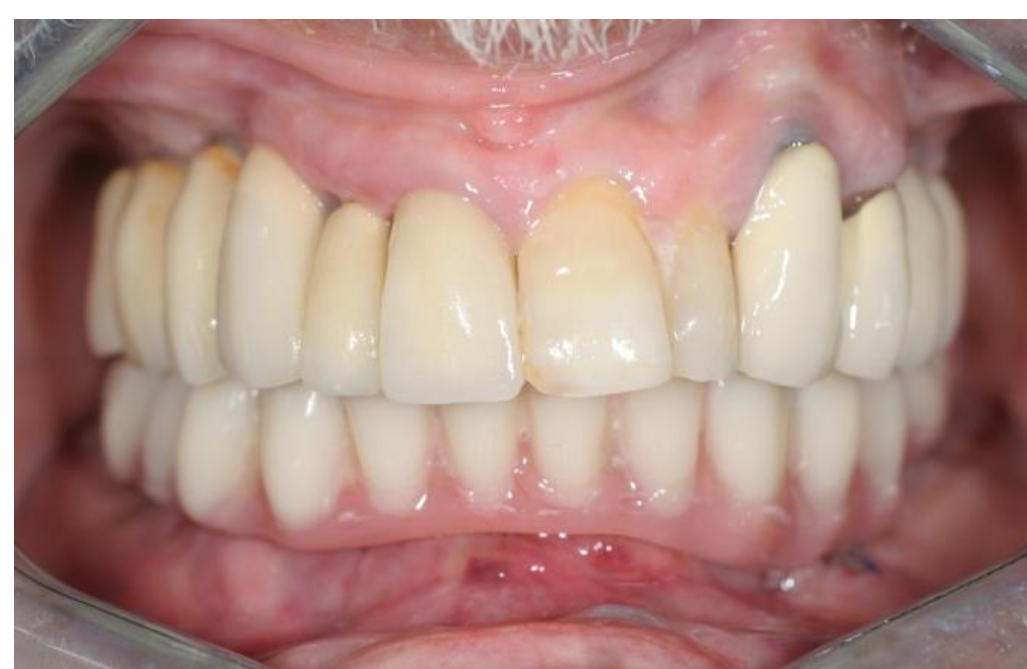all

Dr. Gidi Hallel case: extraction and 4 month follow up

Case GH1



24 hours post op. temporary restorations



Case GH1

Dr. Gideon Hallel DMD MPA