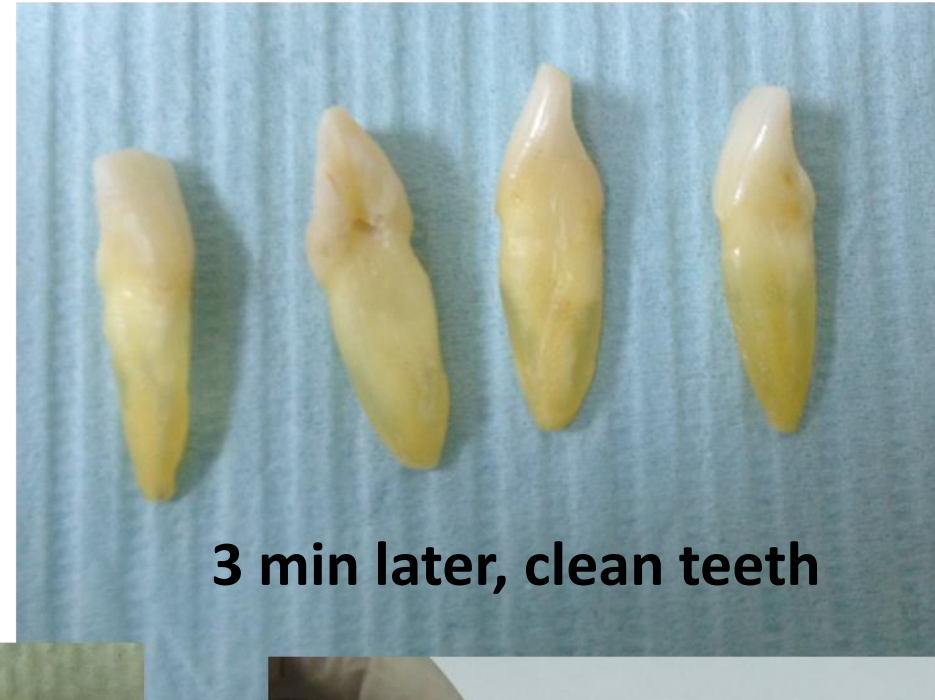
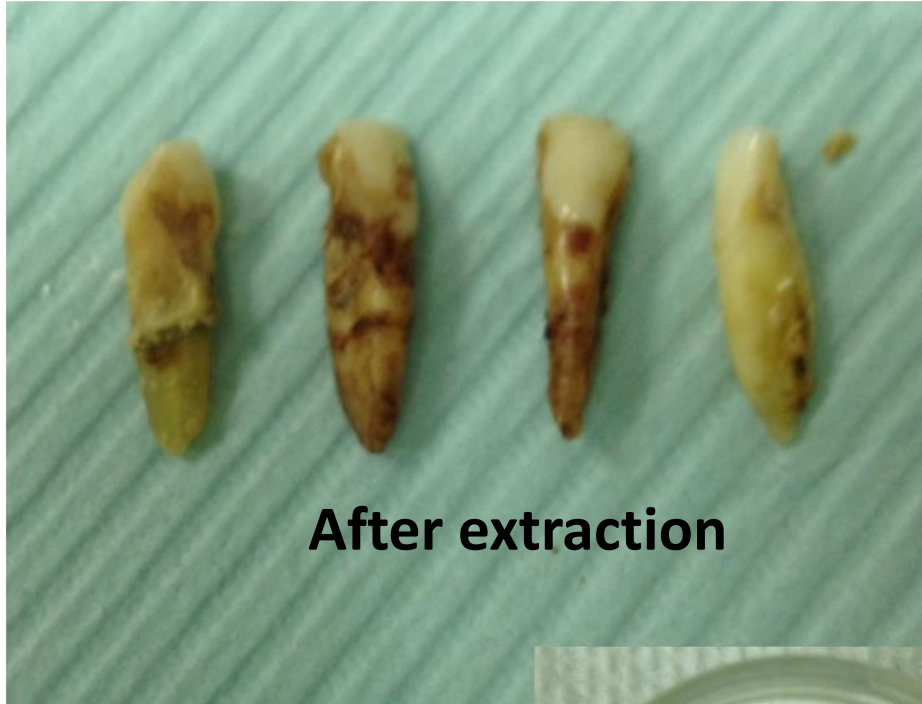
CASE LS3:

4 incisors became 4ml of
autogenous dentin during 15
minutes after extraction!!!


WOOO....

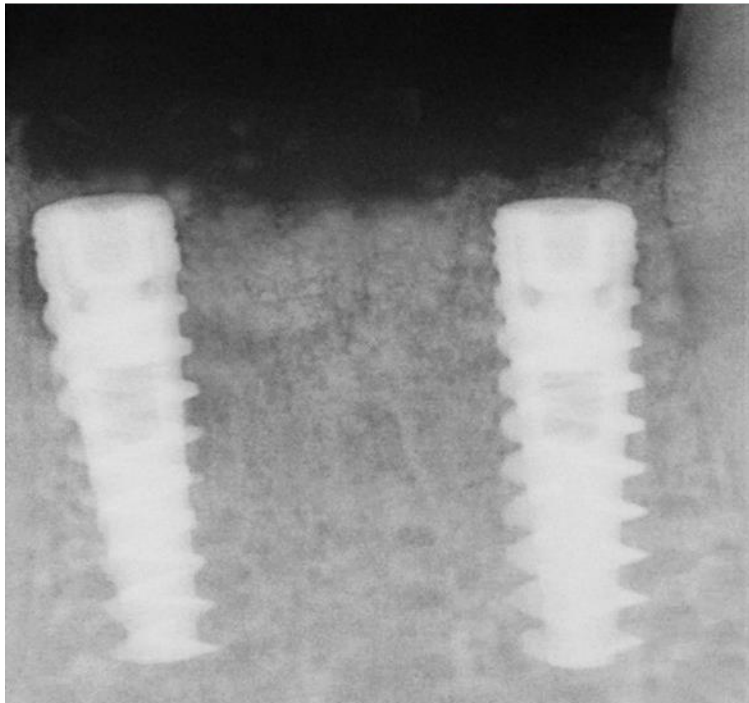
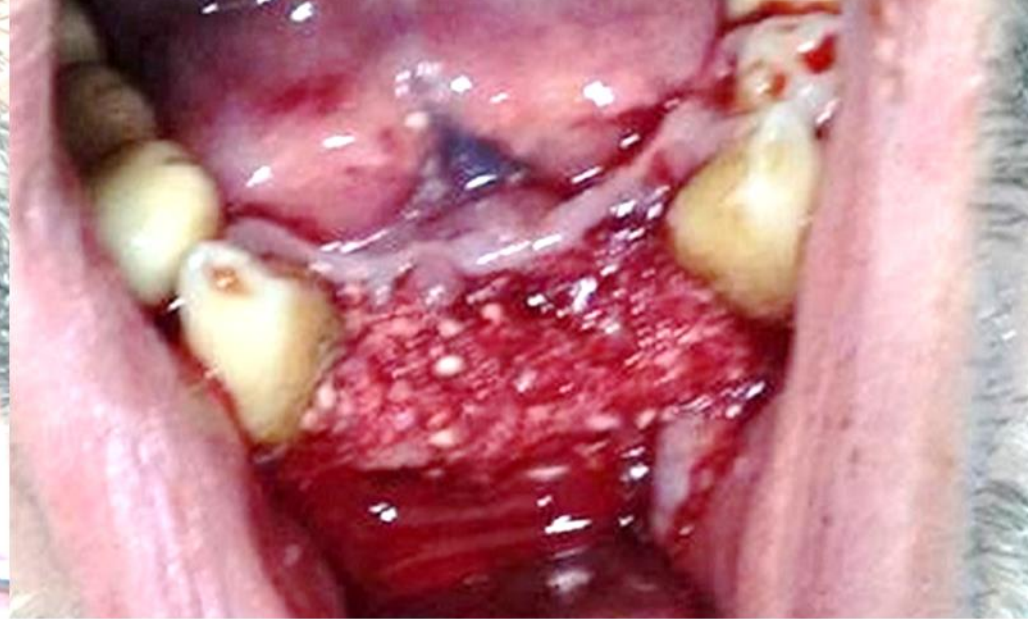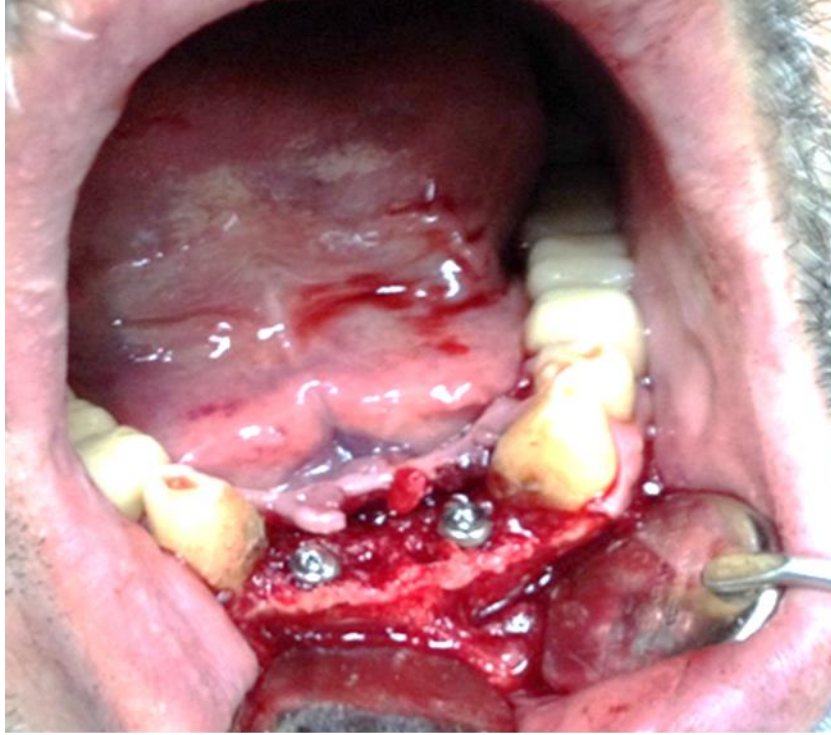
Extracted teeth are prepared by dental assistant during the session of the surgery (the crown part of the teeth is intact).



Case LS3

 KometaBio
Tissue Engineering





*Two implants have been placed through the sockets . Surgical site was augmented by **autologous dentin graft**. The surgical site was closed by PRF and a released flap.*

Case LS3