

CASE LS4

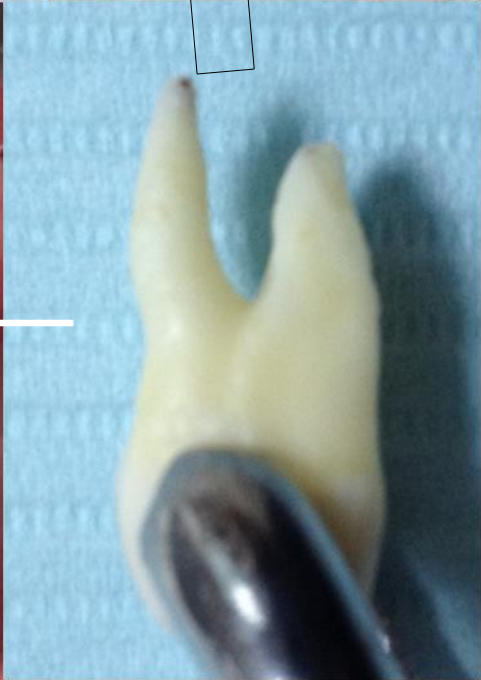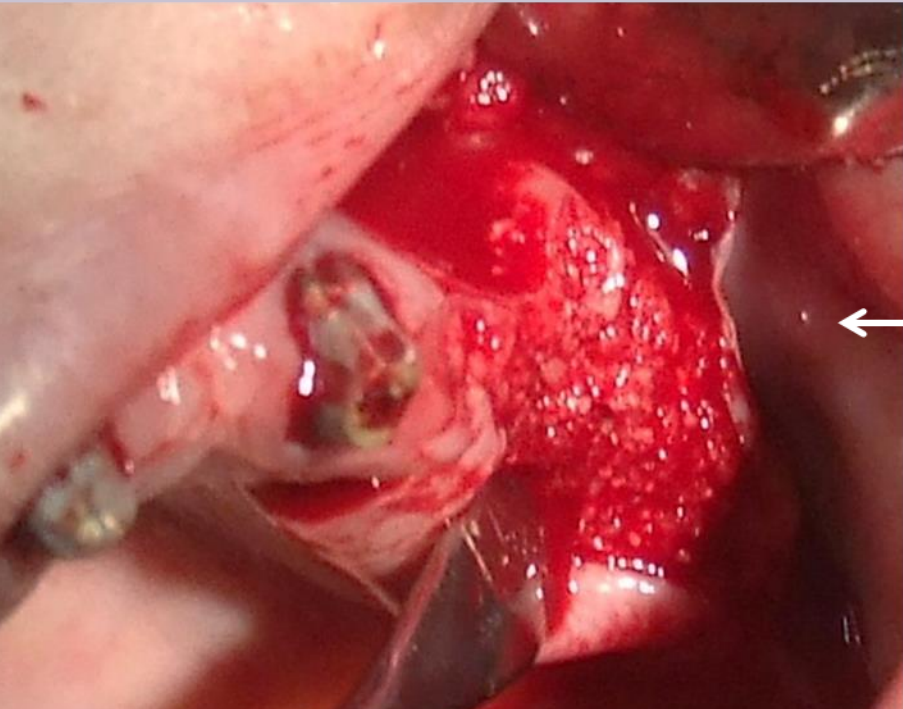
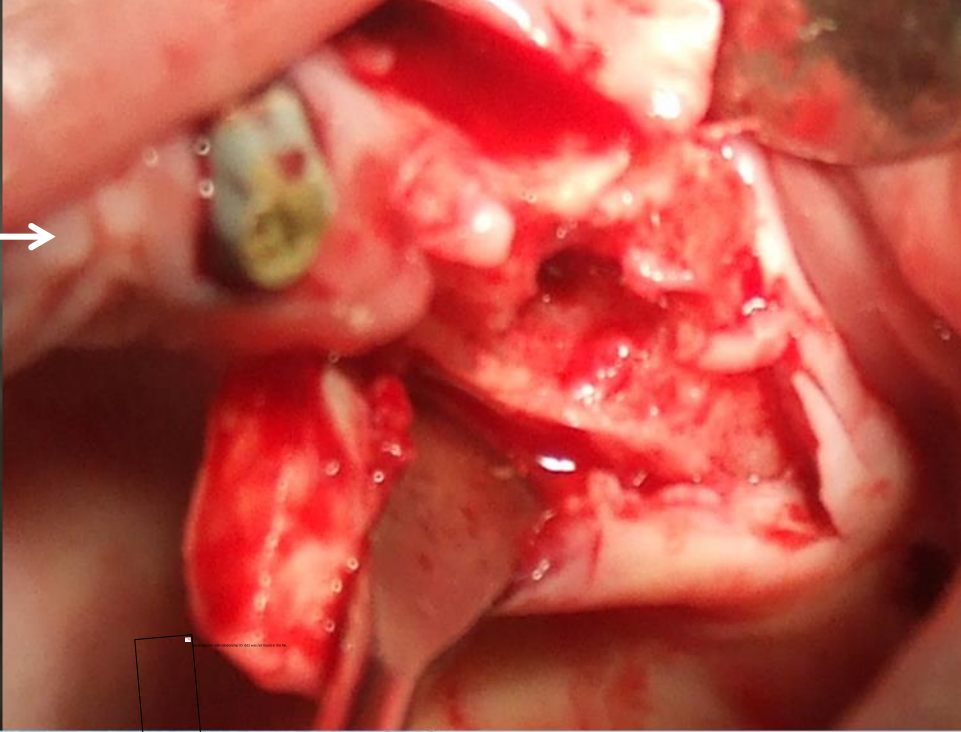
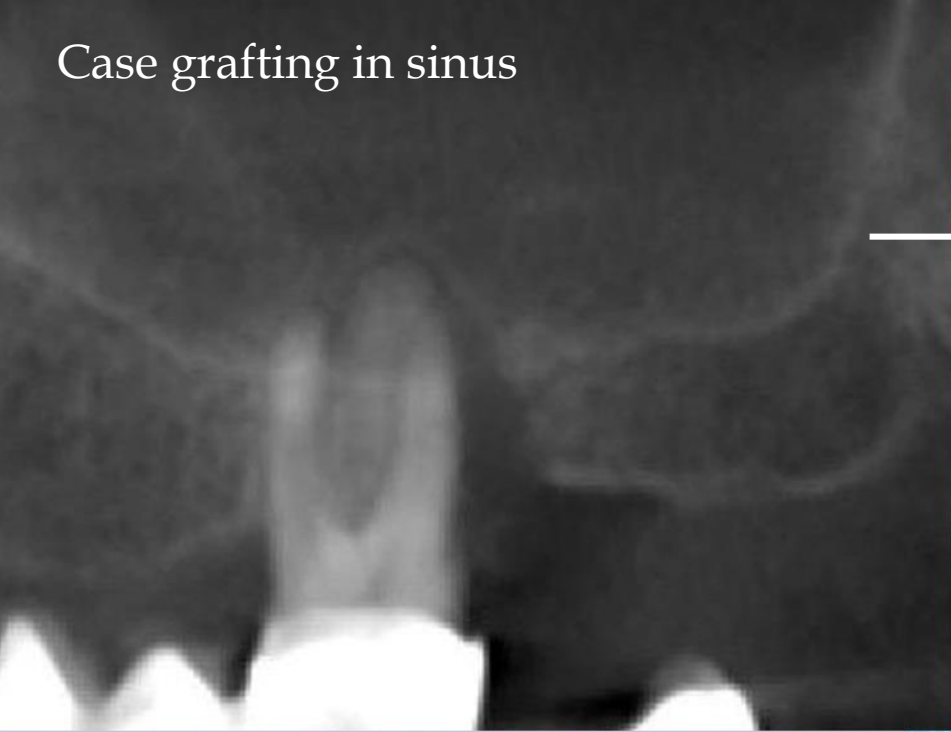Step 1: Extraction of tooth results with perforation of maxillary sinus.

Step 2: Clean of extracted tooth, grinding and cleansing.

Step 3: Grafting of bacteria free autogenous dentin, including grafting into sinus.

Step 4: Closing by PRF membrane and sutures.

Case grafting in sinus

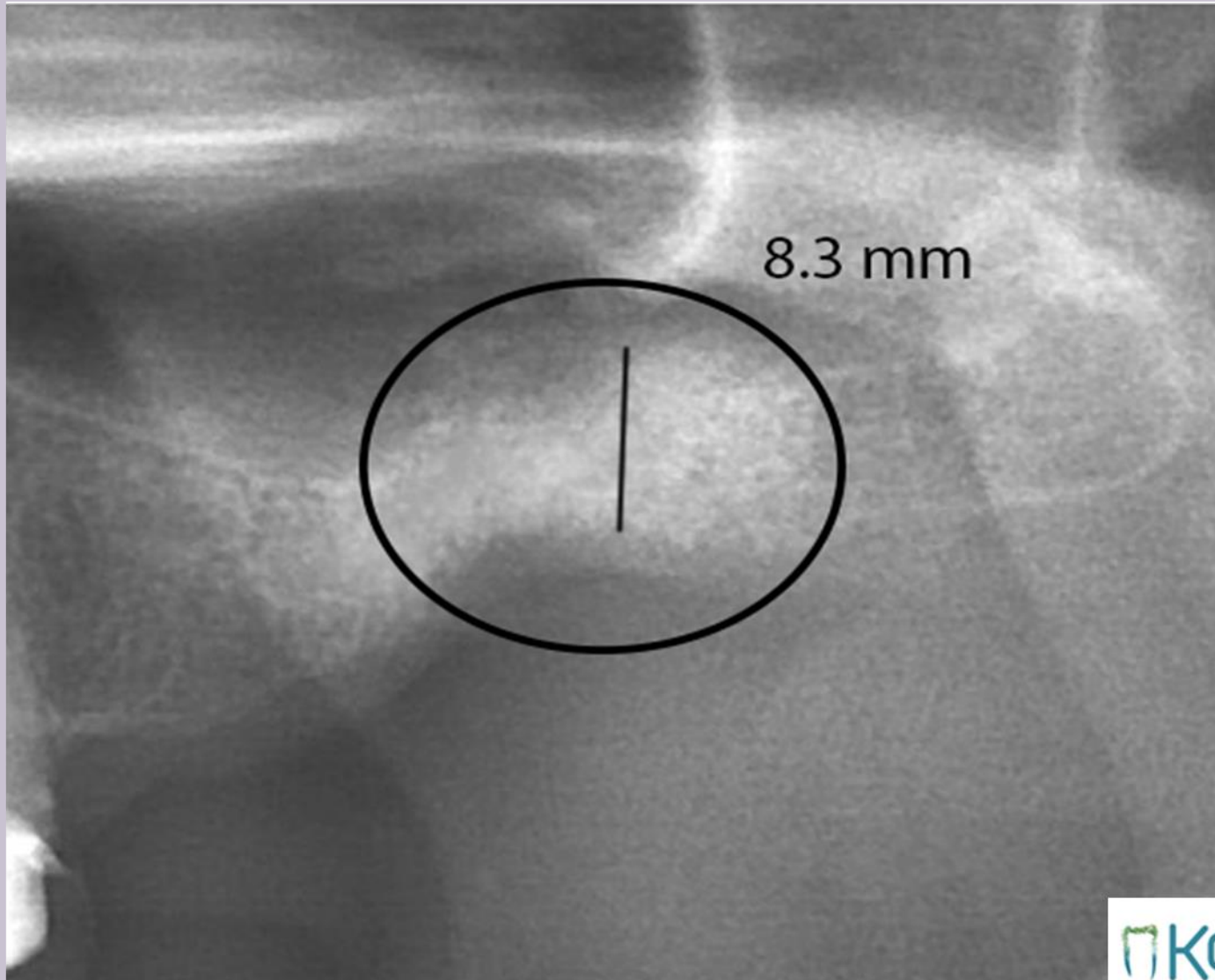


Tooth No.26,
from diagnosis
to dentin grafting

Case LS4

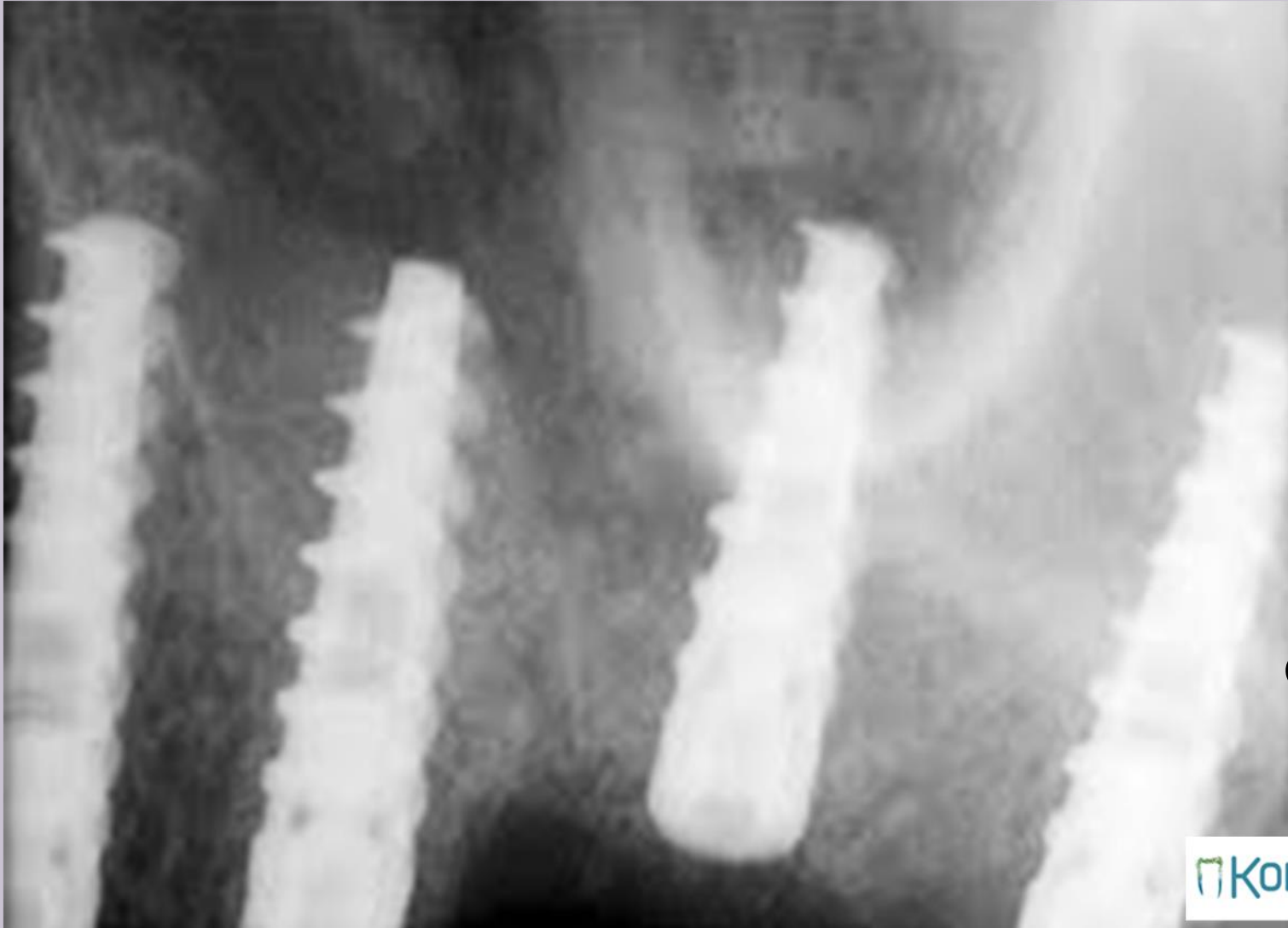

2 month after grafting of dentin



Case LS4

Implants in Dentin-Bone structure



Case LS4